

# Mackenzie Approach to the Shoulder

Lennard Funk

Donald B Mackenzie.  
The Antero-superior Approach for Total Shoulder Replacement.  
Orthop. Traumatol. 2:71-77.(1993)



# Deltopectoral Approach

- ↯ Circuitous route to Glenoid
- ↯ Difficult access to Posterior & Superiorly displaced Tuberosities
- ↯ Rotator interval may be difficult to identify adequately
- ↯ CHL release may be difficult
- ↯ Cephalic vein & Deltoid branch of Thoracoacromial artery - troublesome



# Mackenzie Antero-superior Approach

- ✓ Direct route to Glenoid
- ✓ Easy access to Posterior & Superiorly displaced Tuberosities
- ✓ Direct access through Rotator interval
- ✓ CHL release
- ✓ Cephalic vein & Deltoid branch of Thoracoacromial artery not violated

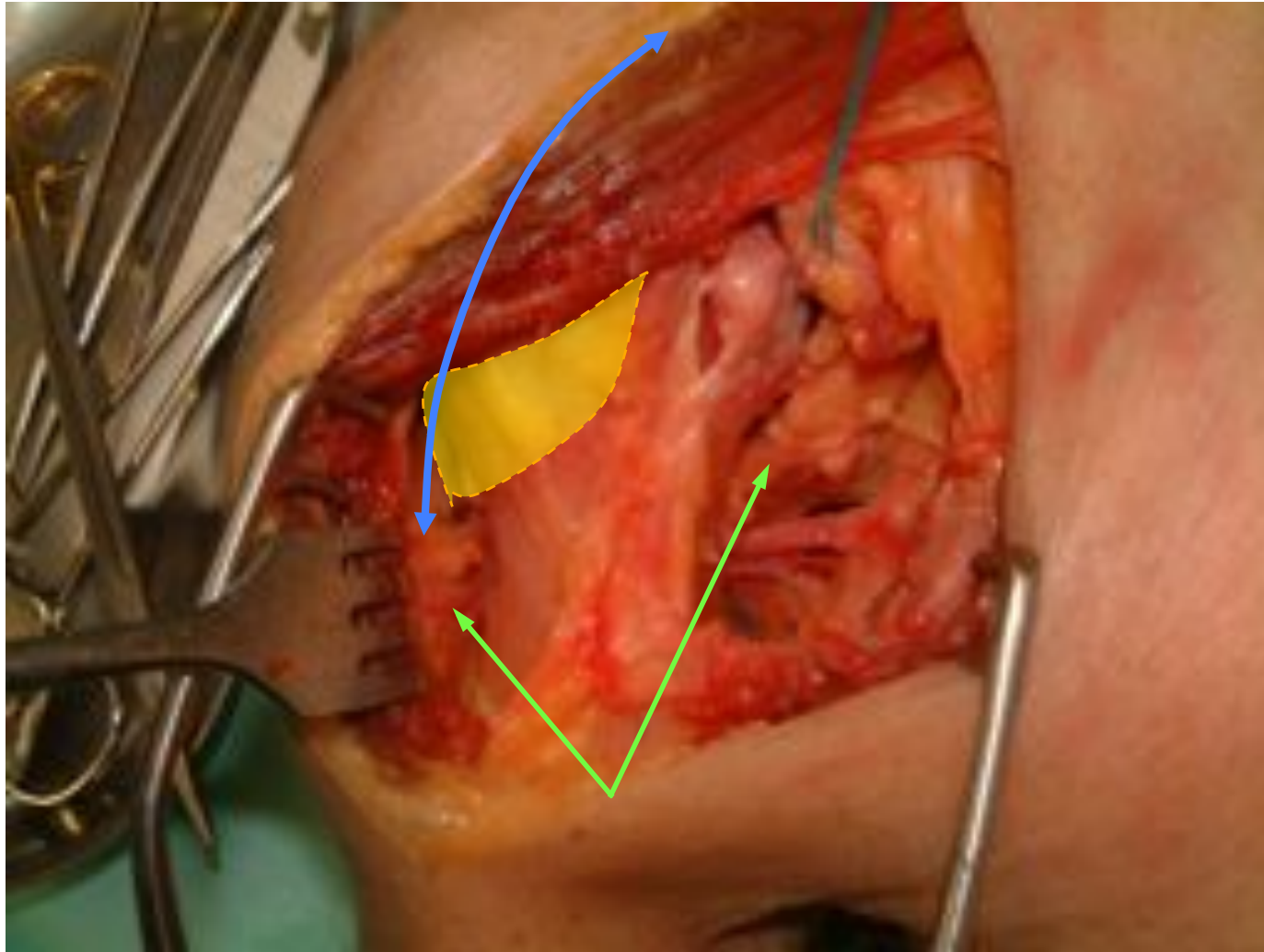


# Axillary Nerve

- Stay in Bursa
- Know Anatomy
- Identify Nerve (vision / palpation)
- Stay Suture



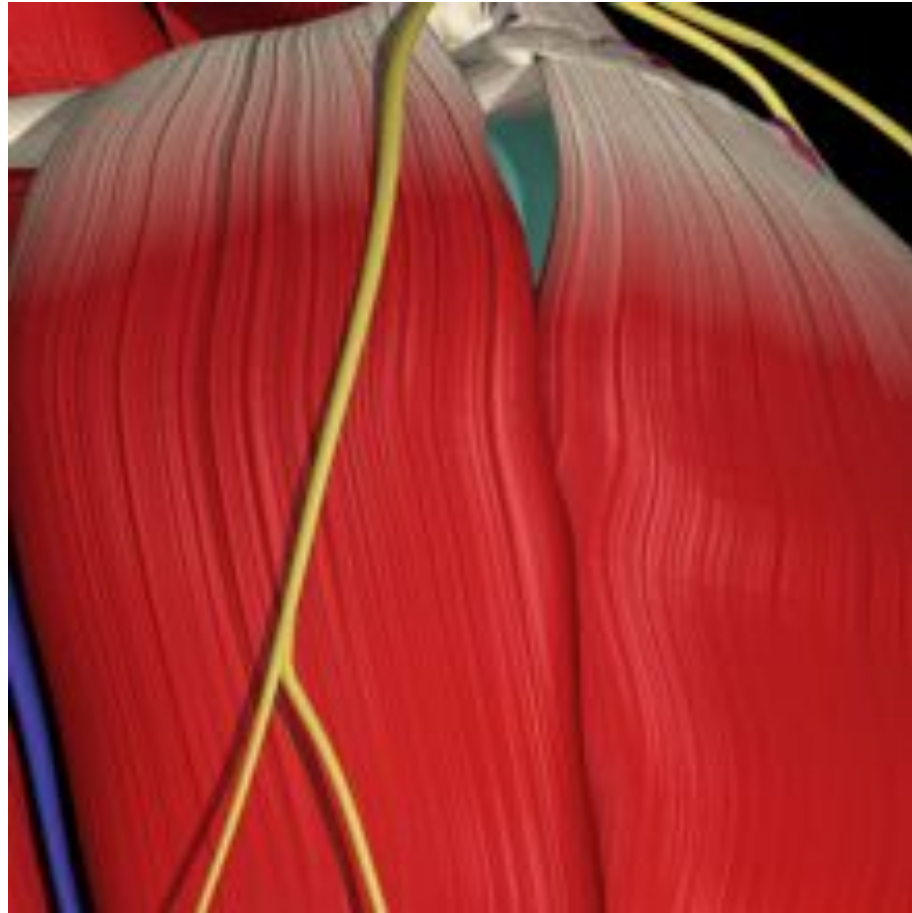
# Axillary Nerve



• • • • • • •  
Orthop. Traumatol. 2:71-77.(1993)



# Axillary Nerve



- - 
  - 
  - 
  - 
  - 
  -
- Orthop. Traumatol. 2:71-77.(1993)



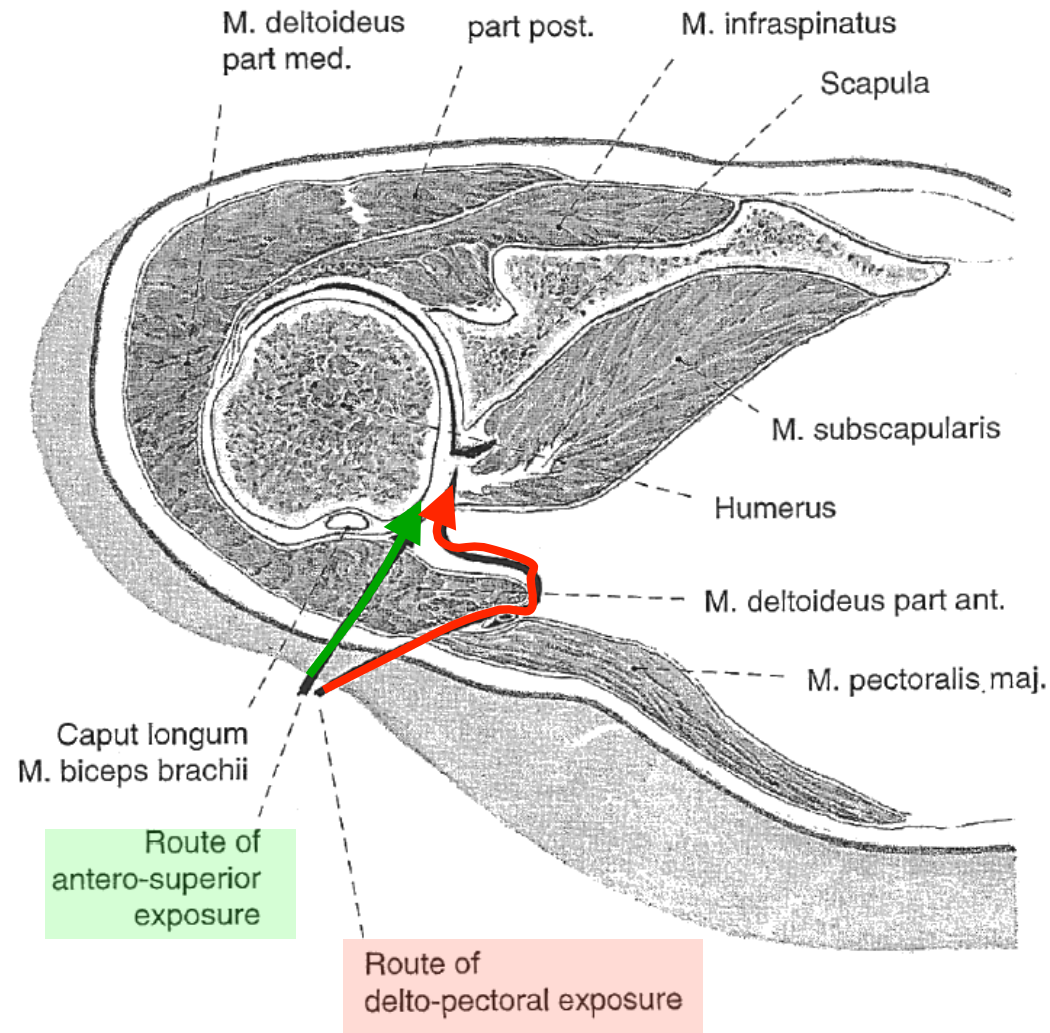
# Axillary Nerve



- - 
  - 
  - 
  - 
  - 
  -
- Orthop. Traumatol. 2:71-77.(1993)

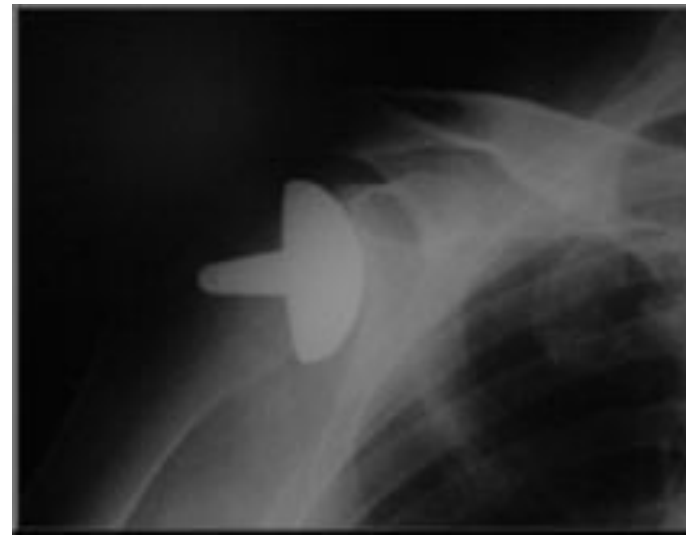
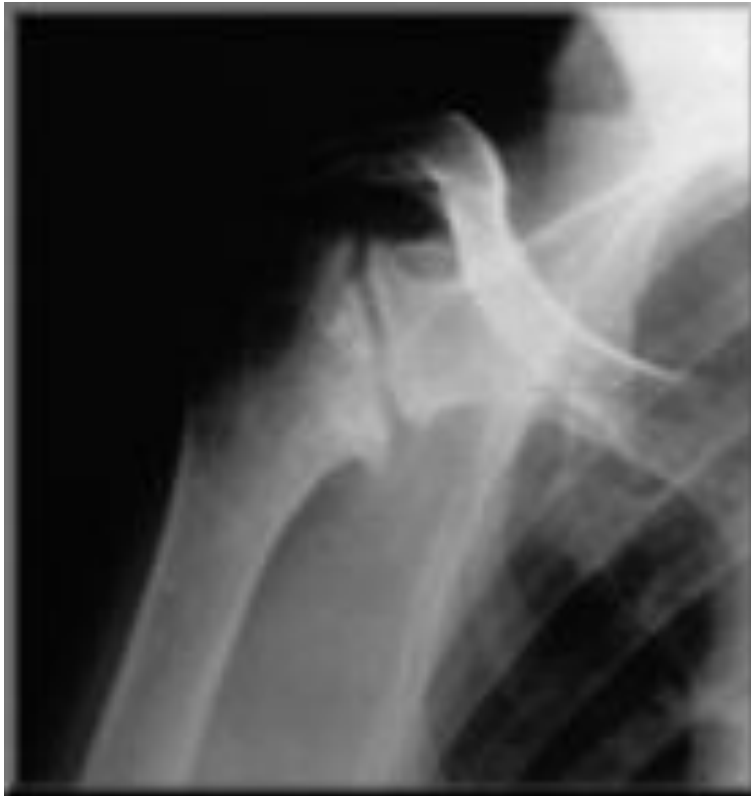

# Deltopectoral Approach





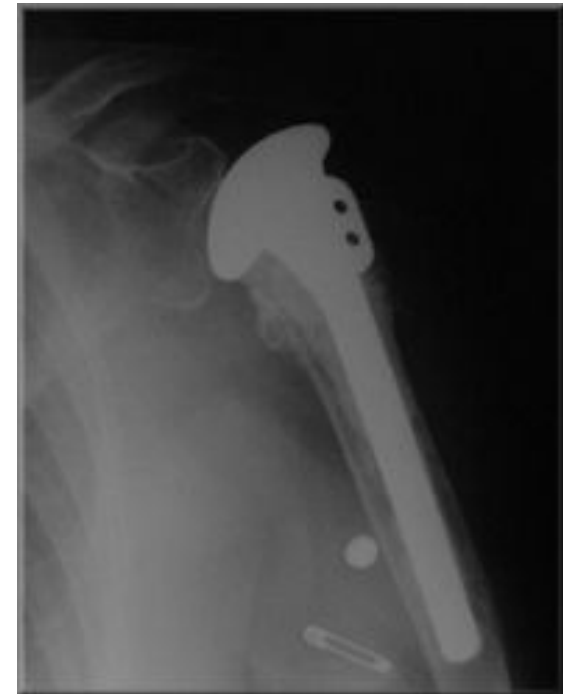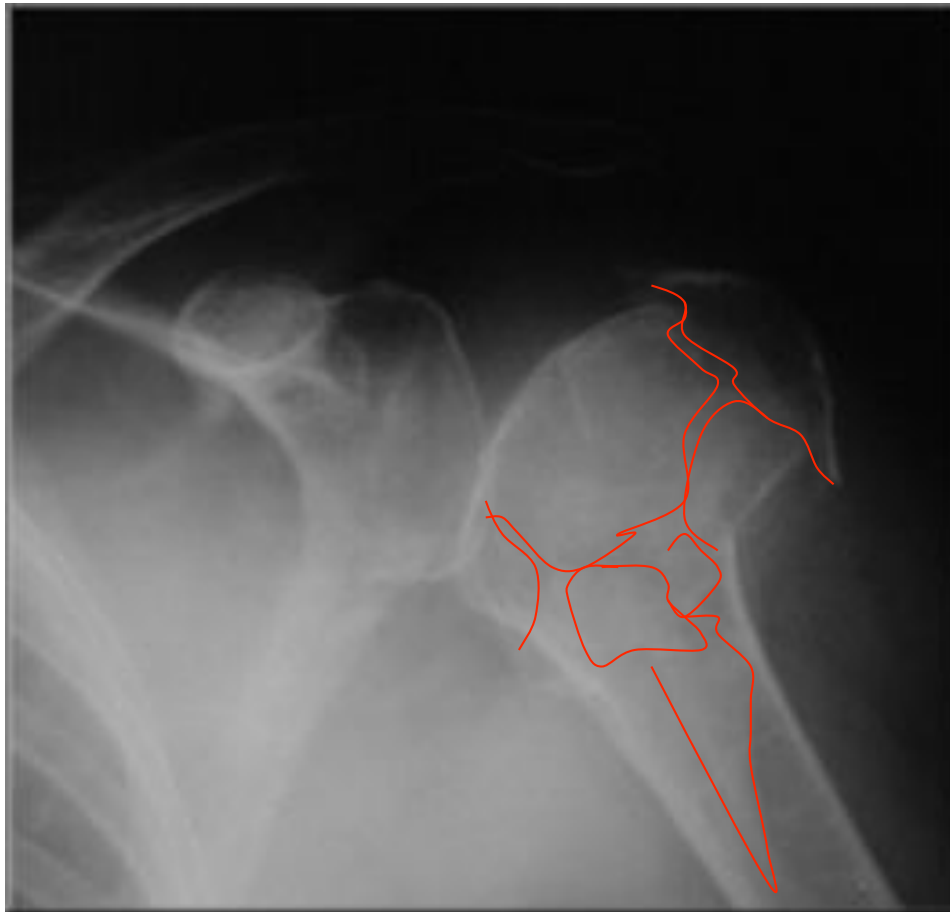
# Elective Arthroplasty



• • • • • • • •  
Orthop. Traumatol. 2:71-77.(1993)



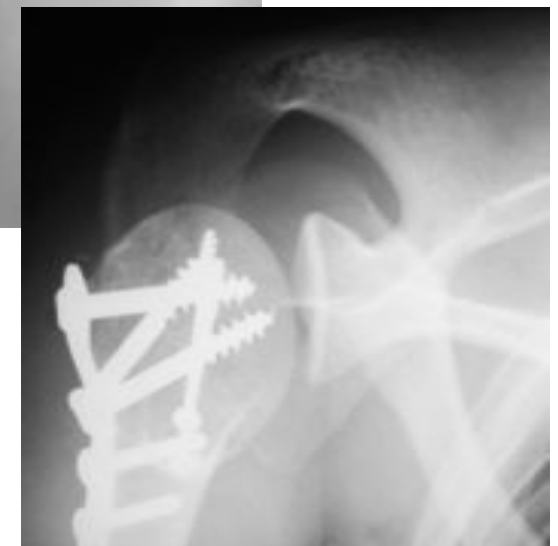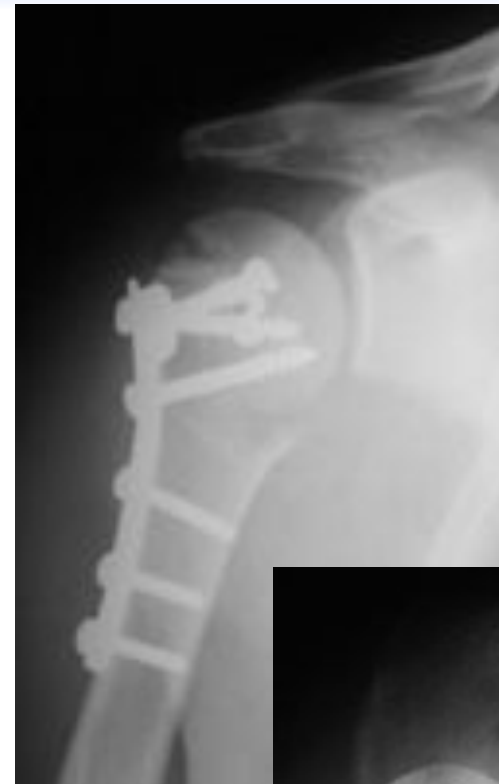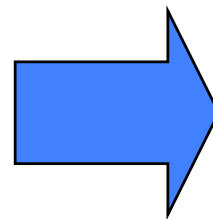
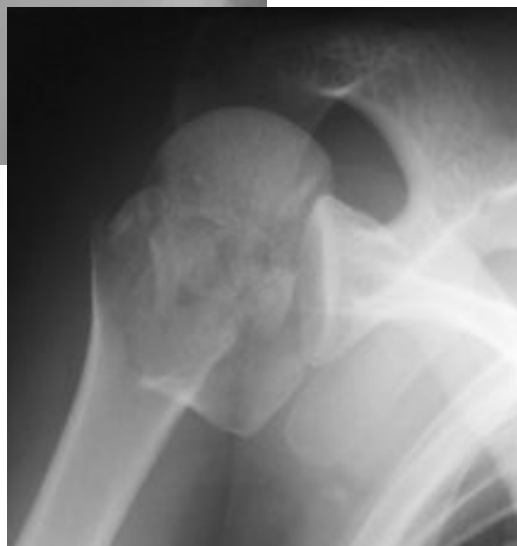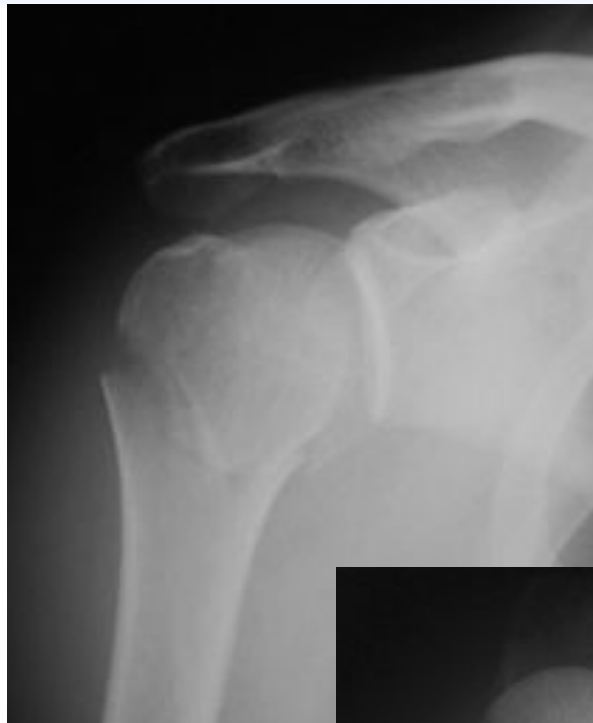# Trauma Hemi



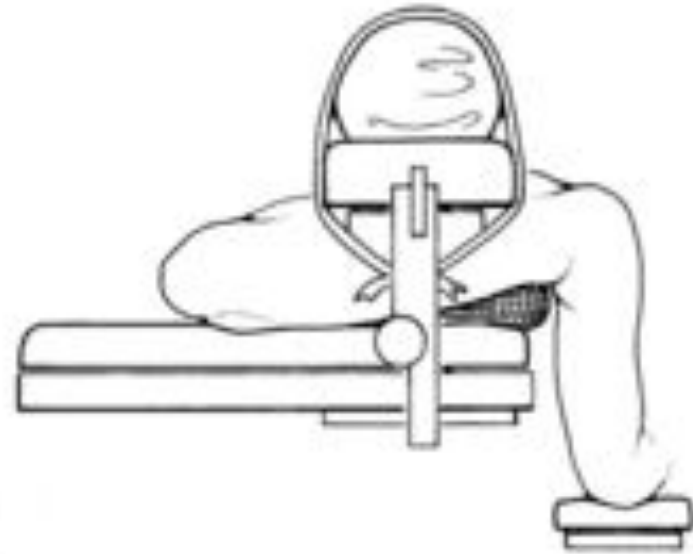
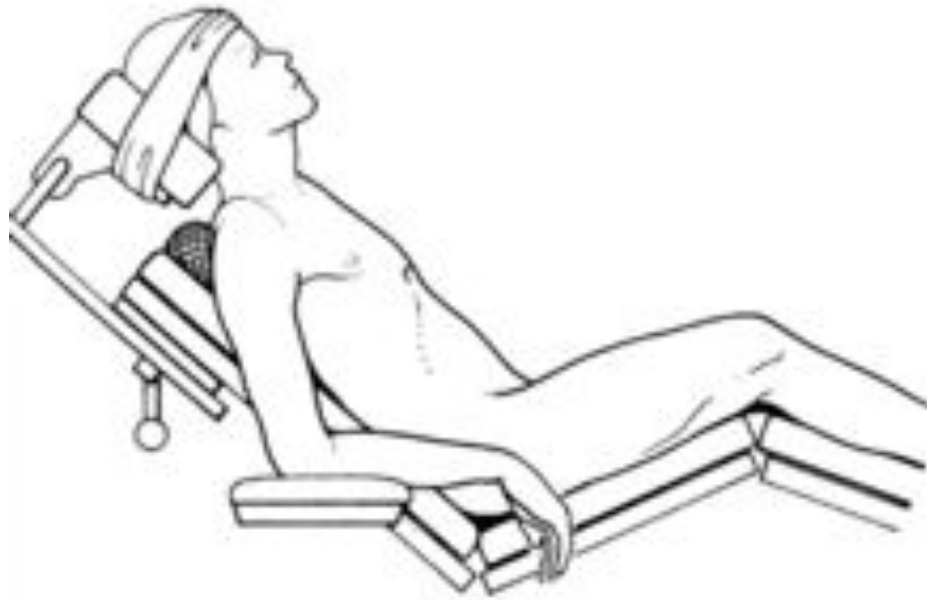
• • • • • • • •  
Orthop. Traumatol. 2:71-77.(1993)



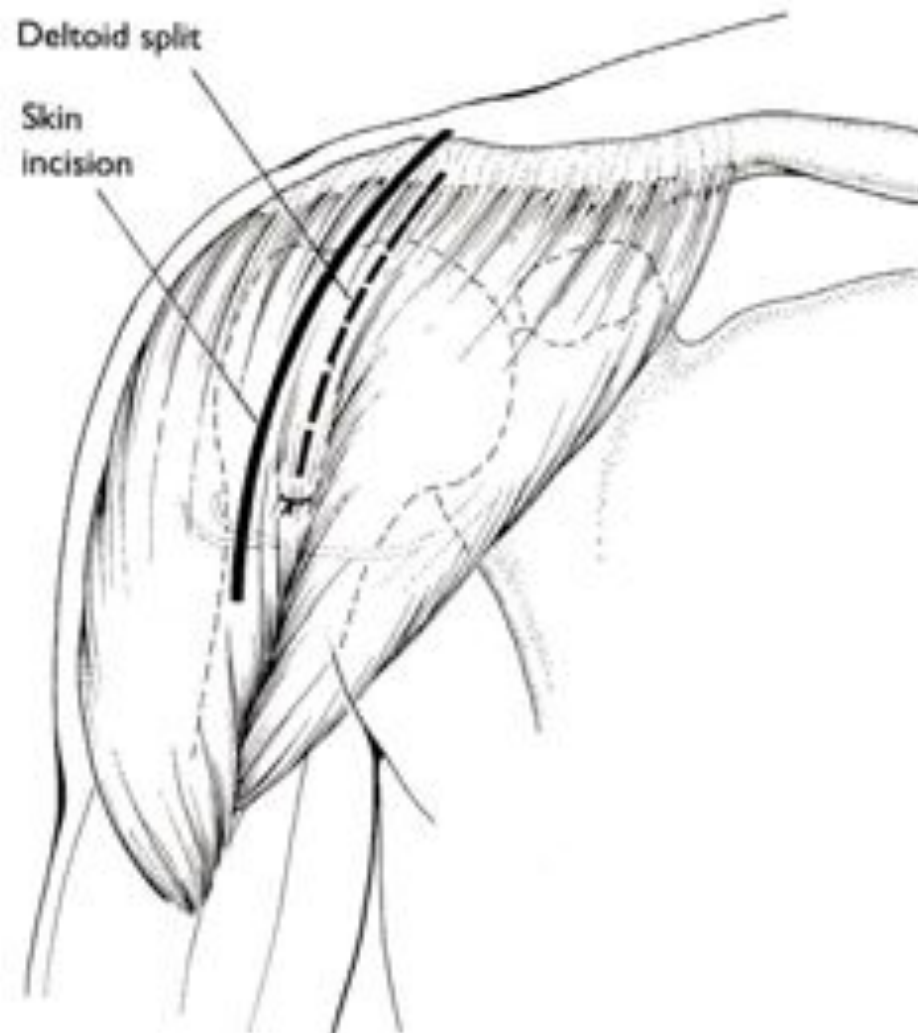
# Fracture Fixation



# Position



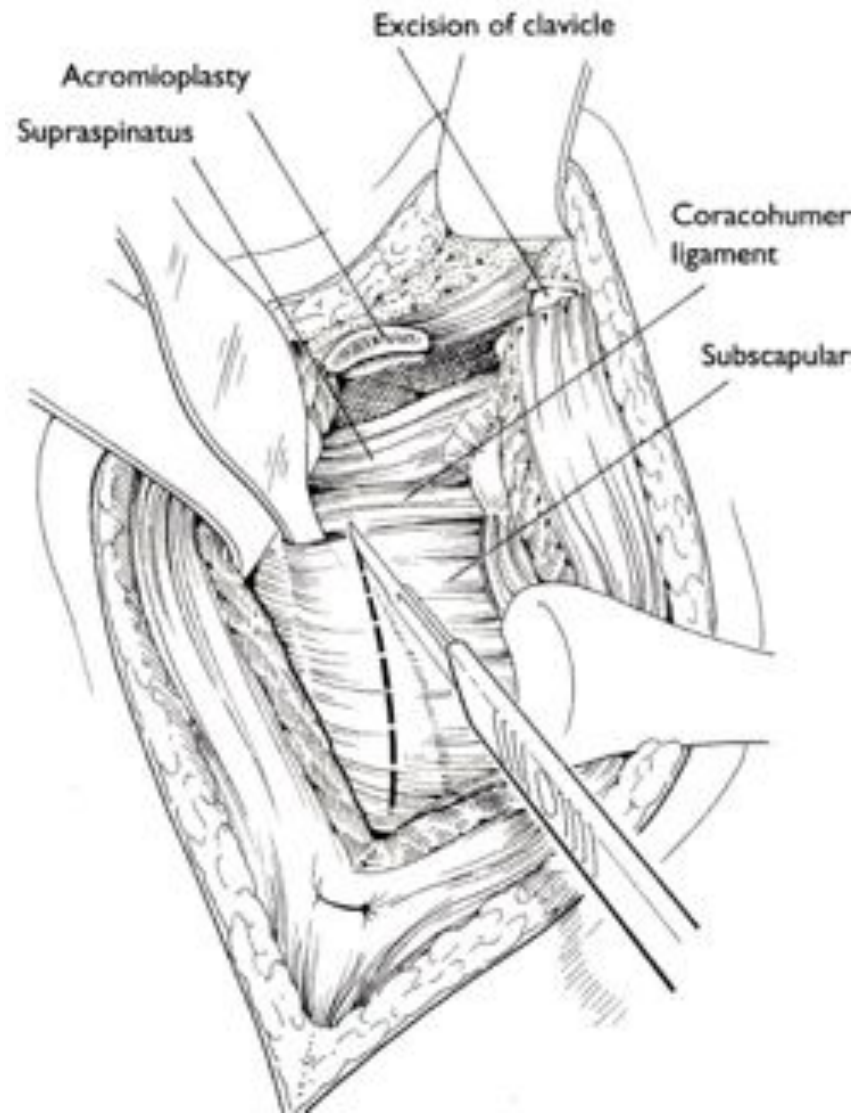
# Incision



• • • • • • • •  
Orthop. Traumatol. 2:71-77.(1993)



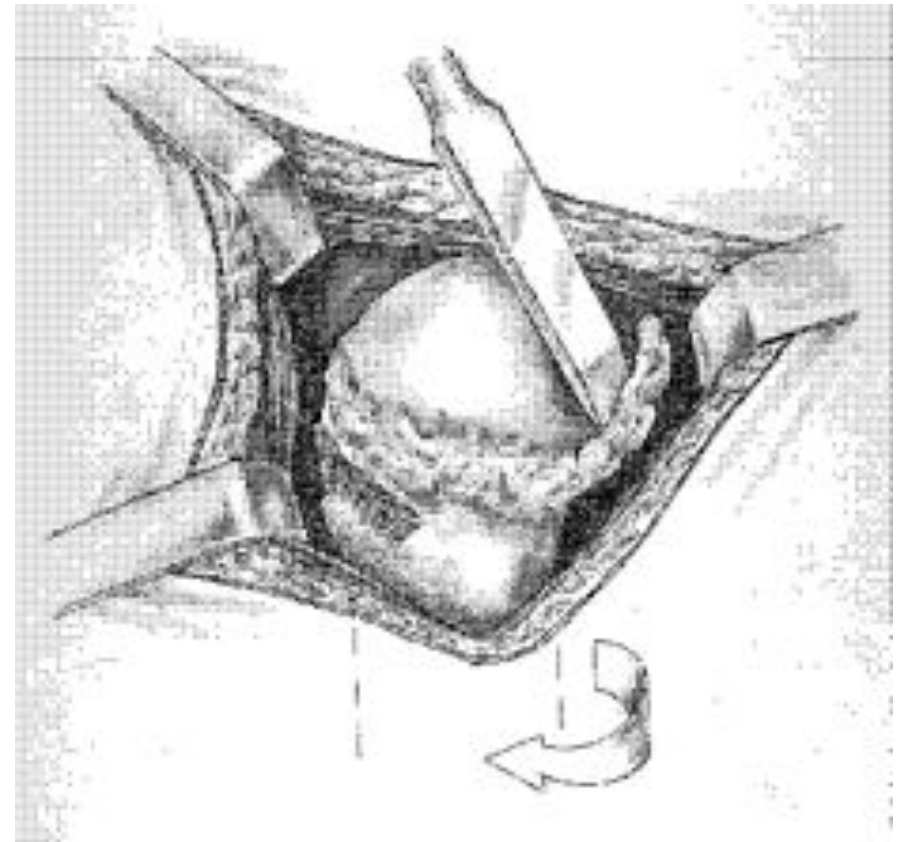
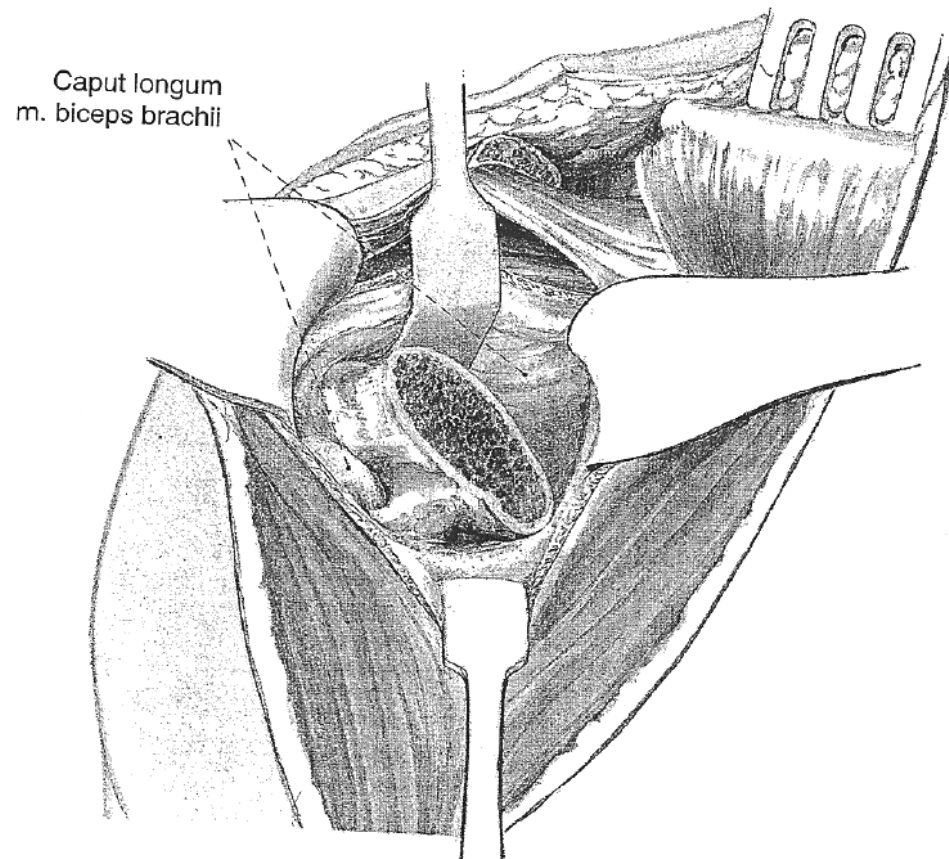
# Approach

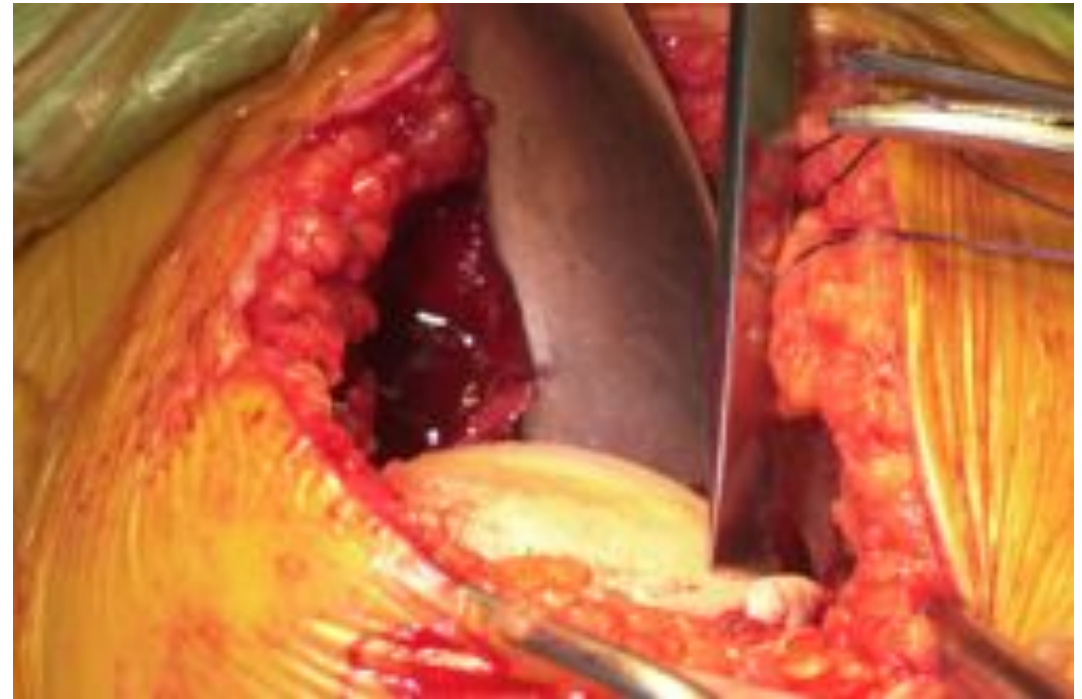
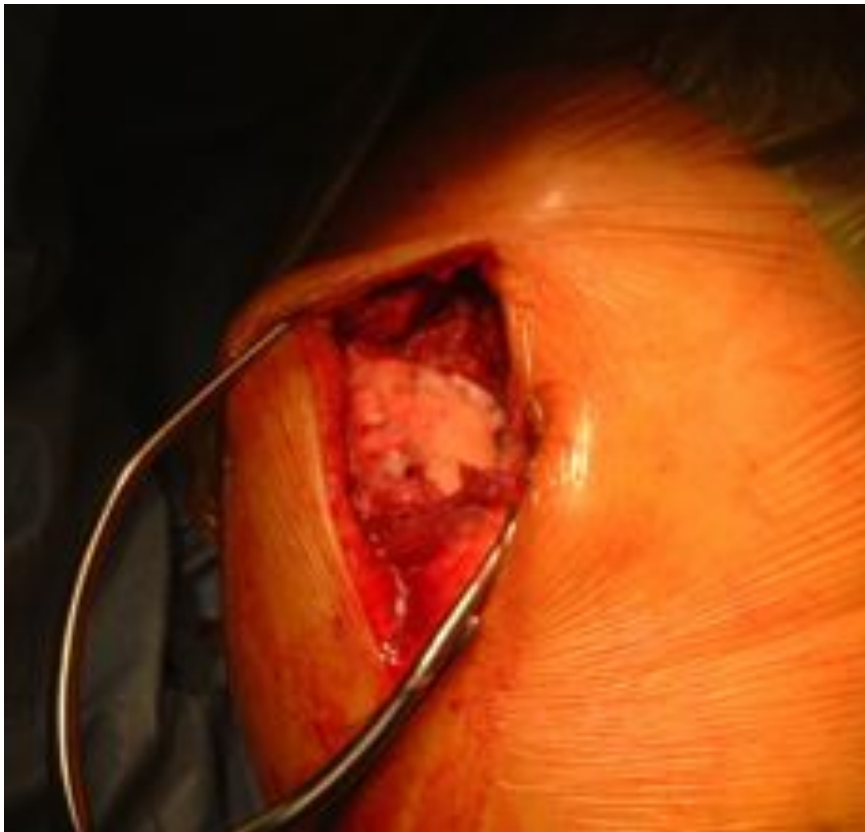


• • • • •  
Orthop. Traumatol. 2:71-77.(1993)



# Humeral Head



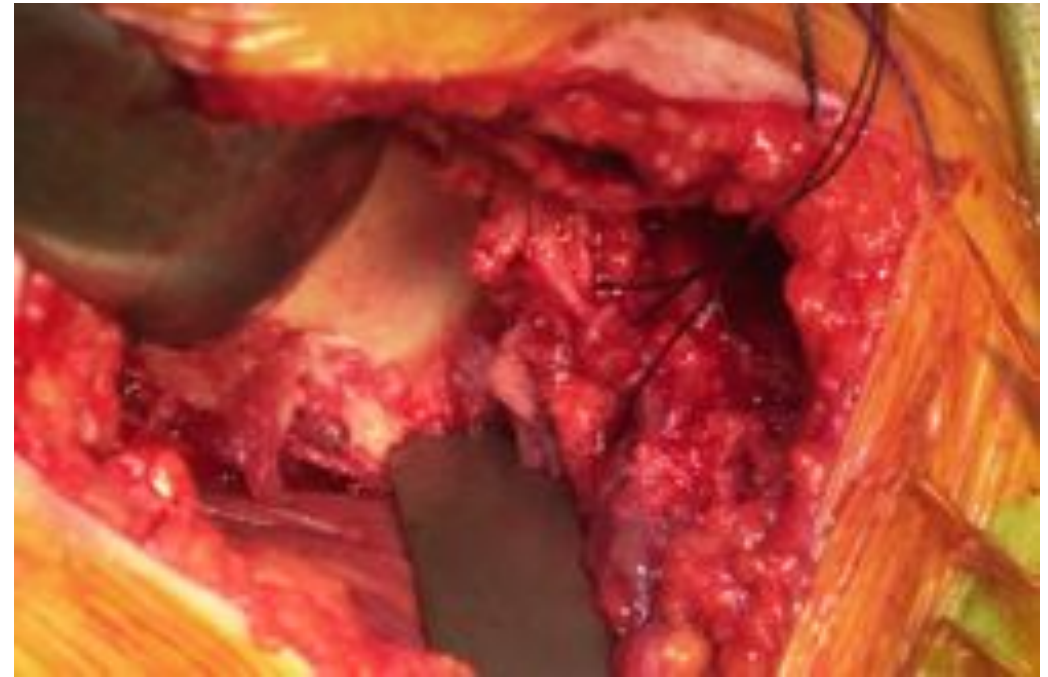
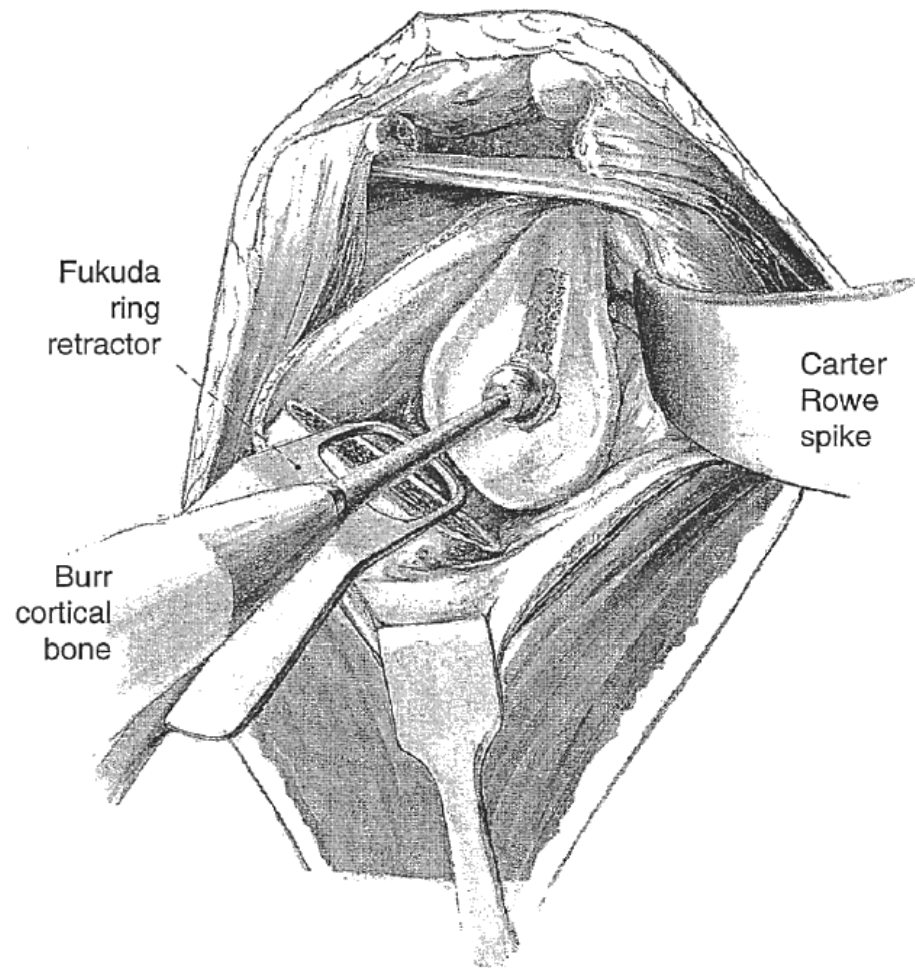


• • • • • • • •  
Orthop. Traumatol. 2:71-77.(1993)

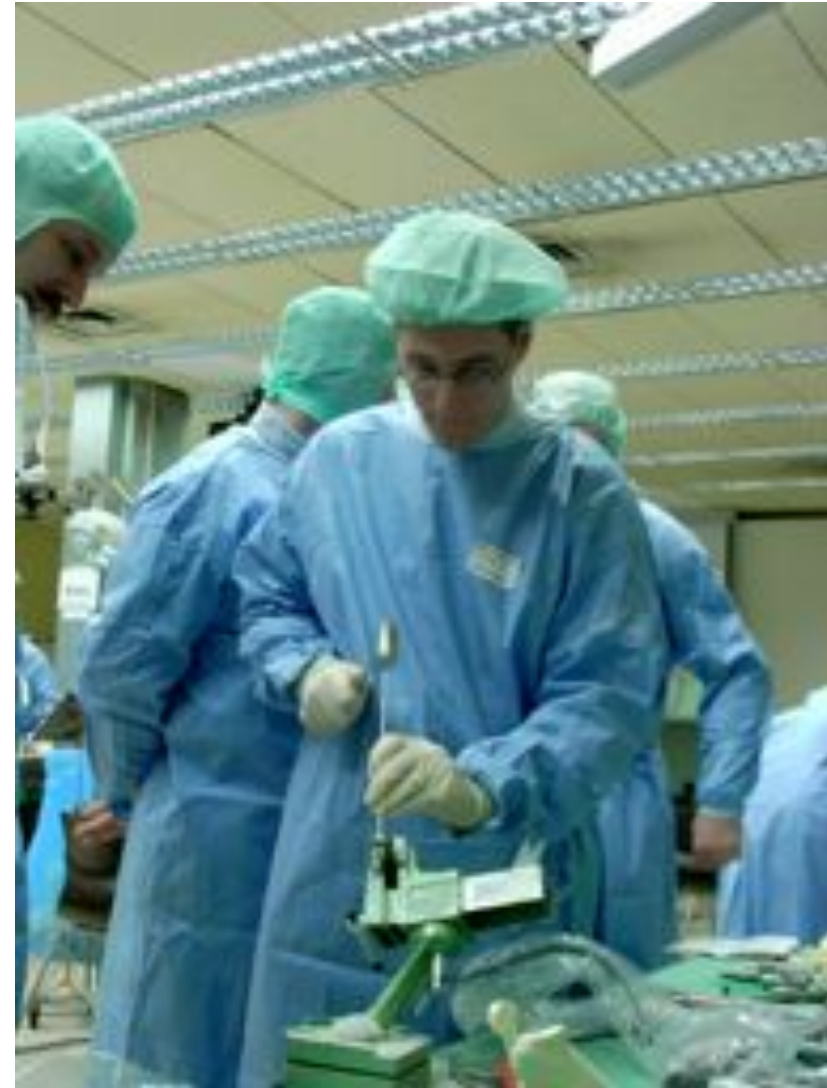
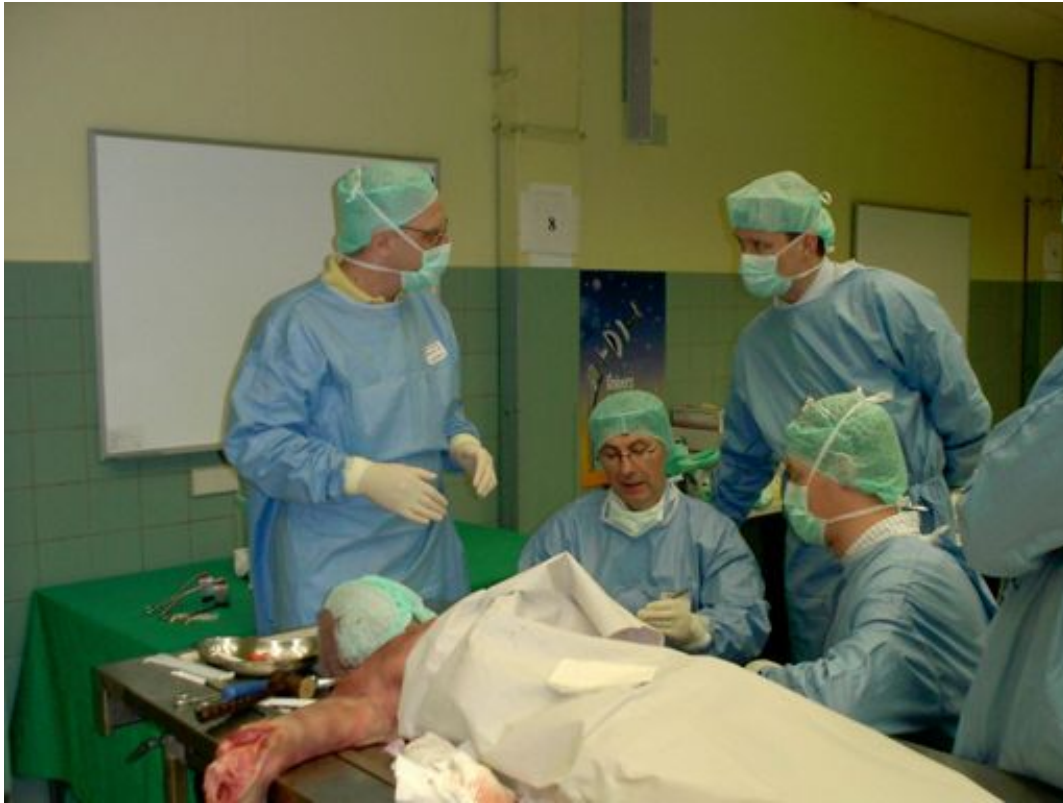


# Glenoid Exposure



# Surgical Approaches Courses



• • • • • • • •  
Orthop. Traumatol. 2:71-77.(1993)

